Stroke: Role of CT Imaging : ??.??????? ???????????

???????? Admin (CME)

??????????? 04 ?????? 2013 ???? 16:11 ?. - ??????????? ???????????? 08 ?????? 2013 ???? 10:53 ?.

Stroke???WHO????.?.1990stroke???????????????????2?? 1999 ??????????????????????????????????????? stroke ???????? 5.54 ????????????????????????????? 2 ??3 ???????????????????????????? ?? stroke??????? 690 ?????????????????[1] ?????????????????????????? ??????????????????????? ????????????????? (Neuroimaging) ??????????????????????????????????????? ???????????????????????????????? ????????????? ??????????????????????????? ??????????????????????????????? ???????????????????????????????????? ??

Stroke: Role of CT Imaging

??.??????? ???????????

????????????????? ??????????????????????????

Stroke ??WHO????.?.1990stroke???????????????????2??1999?????????????????????????????????????stroke???????5.54?????????????????????????????2??3???????????????????????????? ?? stroke ??????? 690 ?????????????????[1] ?????????????????????????? ??????????????????????? ????????????????? (Neuroimaging) ??????????????????????????????????????? ???????????????????????????????? ????????????? ??????????????????????????? ??????????????????????????????? ???????????????????????????????????? ??

??? ?????????? ???????? Computed tomography scan (CT) ???????

????????????????????? ????????? ???? infarction ???????? 4 ??????????

1. Hyperacute infarction ??????? ????????????????????????????? ????? 3 – 6 ?????????? ??????????????????????? therapeutic window ?????????????????? reversible ??

2. Acute infarction ??????? ??????? 6 ??????? ????? 24 ??????? ??????????????

3. Subacuteinfarction???24????????????6??????????earlysubacute(???????????????) ??? chronic subacute (?????????????????????? 6 ???????)

4. Chronic infarction ??????? ??????????????? 6 ??????? ????????????????? stroke ?????????

?? modality ????????????? CT scan, MRI ??? angiography ??????

CT scan (2-3, 4-6,7-11)

???????????????????CTscan??????????????????????stroke???

1. ??????????????????????????? stroke ????? hemorrhage ???????? hemorrhage? ??????????????????????????????? management ?????????????

2. ???????????????????????????????? Stroke ???? ??????????? aneurysm, vascular malformation ???? Tumor ???????????????? Stroke ???

???????????????? CT scan ?????? stroke ??????????? hemorrhage ?????????????? hyperdensity ??? hematoma ???????????? CT number ??????????????? attenuation coefficient value ??????? 60 – 100 HU ????????????????????????????????????? hypertensive bleeding, ruptured ??? vascular malformation, aneurysm, amyloid angiopahy, venous occlusion, drugs ??????? ???????? bleeding disorders ???????

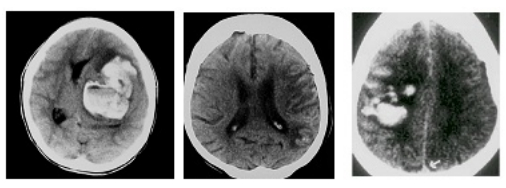

A B C

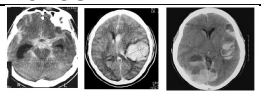

D E F

Fig.1A-F ???????CT brain ??????? intracranial hemorrhage ????????????????????????????

A= HT hemorrhage, B= hemorrhagic transformation ??? MCA infarction, C= hemorrhagic venous infarction, D= Subarachnoid hemorrhage ??? ruptured aneurysm, E= AVM ruptured, F=bleed ??? coagulopathy

???? cerebral infarction ???????????? CT scan ????????????????????????????????????? onset ??? Stroke ??????????????????????????? CT scan ???????? hyperacute (?????12 ??.), acute

(12 – 24 ??.) subacute (24 ??.??? 6 ???????), chronic (6 – 8 ??????? ?????????) ??? hypodensity ????????????????????????? ???????? cytotoxic edema ????????????????????? density???? ?????? hyperacute ?????? hypodensity ??CT ?????????? ???? “hyperdense artery” ????? 25-50 % ??? obscuration ??? lentiform nucleus ??? ?????????? acute ??? ???? hypodense lesion ????????????????????????????????? white matter ????????????????? gray–white matter ????????????? density ????????????? “loss gray – white matter interface” ??? ??????????????????????????? cerebral sulcus ??????????????????????????? ????? “sulcal effacement” ???????????? 24 ??.??? 1 ?????????????????????? subacute ??enhancement (???????) ?????????????????????? hetergenous enhancement ???????? gyriform enhancement ???????????????? subacute stage????????????????????????????????? cortical area

?????????????Chronic(???????8???????)??gliosis????????????????????? volume loss ???

???????????? CT ?? ???? cerebral infarction??

	CT FINDINGS							
	Hypodense area	Hyperdense artery	Loss gray-white	Sulcal effacement	Mass effect	Hemorrhagic transformation	enhancement	Volume loss
Hyperacute	-	+	-	-	-	-	-	-
Acute	+	-	+	+	+	-	-	-
Subacute	++	-	+	++	++	+	+	-
Chronic	++	-	-	-	-	-	-	+

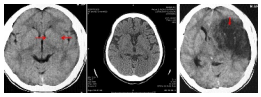

A B C

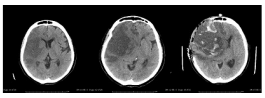

D E F

Fig. 2A ??? CT brain ????????????????????????????(?????) ??? (???? hyperacute) **Fig.2B** ????????????????????????????? ??? cerebral sulci ???? (????acute) **Fig.2C** ??? mass effect??????(????subacute) **Fig. 2 D-F** ??? CT brain, 3?? acute(2D), subacute (2E) ????????????????????????????? (hemorrhagic transformation) (2F)

?????????????????? CT ????????????? scan time ???? ??????????? multidetector – row CT(MDCT) ????????????????????????????????? ????????????????????????????????? slice ???????? 1 ????????? ??? artery to artery emboli ??? atheromatous plaque, arterial occlusive disease, arterial dissection ??? dural venous sinus thrombosis ?????????? MDCT ?????????????????????????? coronal ??? sagittal ?????????????????????????????????????? cranium ??? neck ???????????????? 3 ??? ???????????? ??????

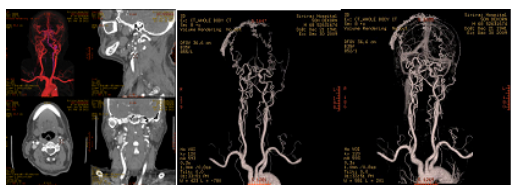

A B C

Fig. 4A-C ??? MDCT CTA ?? 2 ???? (??? gray scale) ??? 3 ???? (?????????????????)(4A), ?????????????????????????3??(4B,4C)??????????????????360????

?????????????

1. Poungvarin N. Stoke in the developing world. Lancet 1998:325:(suppl III)1922
2. Runge VM. Clinical MRI: Brain ischemic (and atrophic) disease, pp.48-77, W.B. Saunders Company, 2002
3. Osborn AG. Diagnostic Neuroradiology: stroke, pp.330-398, Mosby-Year book, Inc. 1994
4. Tomandl FB, Klotz E, Handschu R, et al. Comprehensive imaging of ischemic stroke with multisection CT. Radiographics 2003;23:565-592.
5. Venketasubramanian N, The epidemiology of stroke in ASEAN countries-A review, Neurol J Southeast Asia 1998;3:9-14
6. Grotta CJ, Ciu D, Lu M, Patel S et al. Agreement and Variability in the interpretation of Early CT Change in Stoke Patients Qualifying for intravenous rtPA Therapy. Stoke 1999;20:1528-1553
7. Bryan RN, Levy LM, Withlow WD et al: Diagnosis of acute cerebral infarction : comparison of CT and MR imaging, AJNR 12:611-621,1991
8. Bastaianello S, Pierallini A, Colonnese C et al: Hyperdense middle cerebral artery CT sign, Neuroradiol 33:207-211,1991
9. Tomura N, Uemura K, Inugami A et al: Early CT finding in cerebral infarction : obscuration of the lentiform nucleus, Radiol 168:463-467,1988.
10. Leys D, Pruvo JP, Godefroy O et al: Prevalence and significance of hyperdense middle cerebral artery in acute stroke, Stroke 23:317-324,1992.
11. Tomsick T, Brott T, Barsan W et al: Thrombus localization with emergency cerebral CT, AJNR 13:257-263,1992